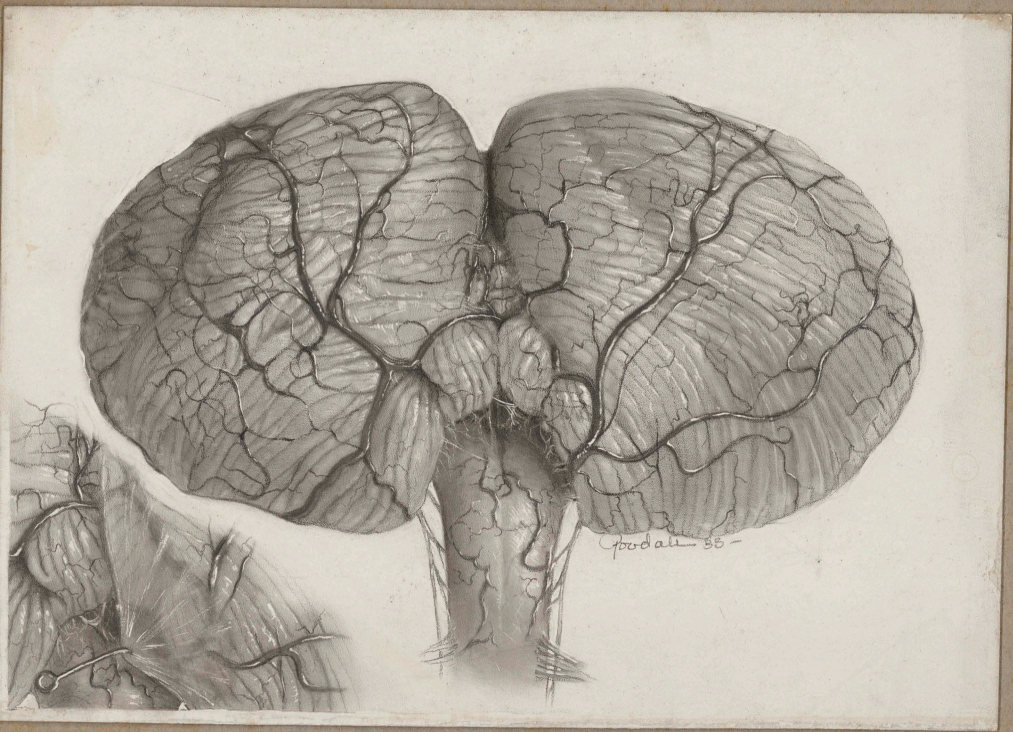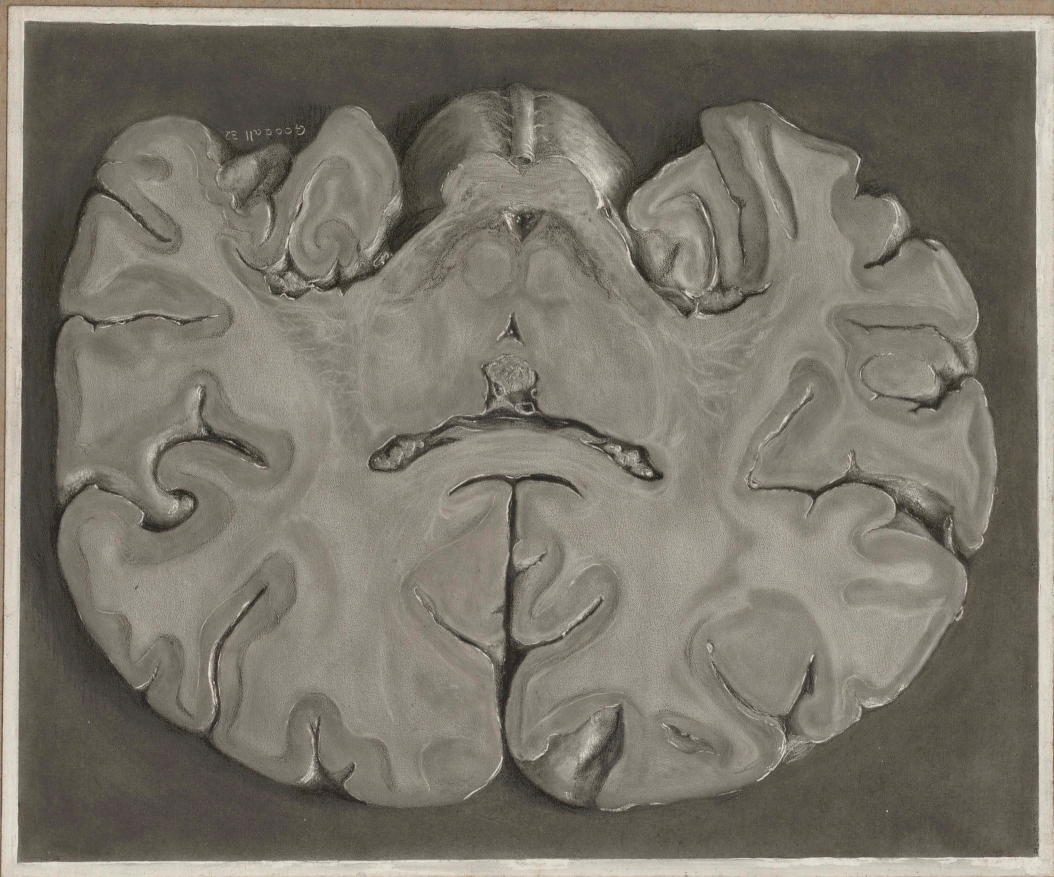
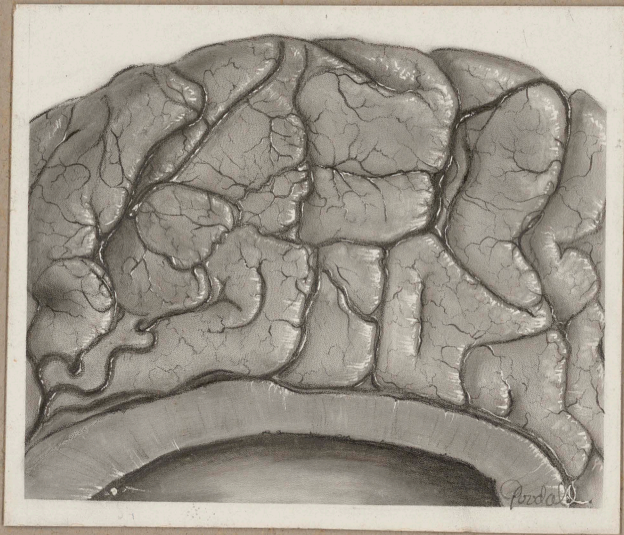


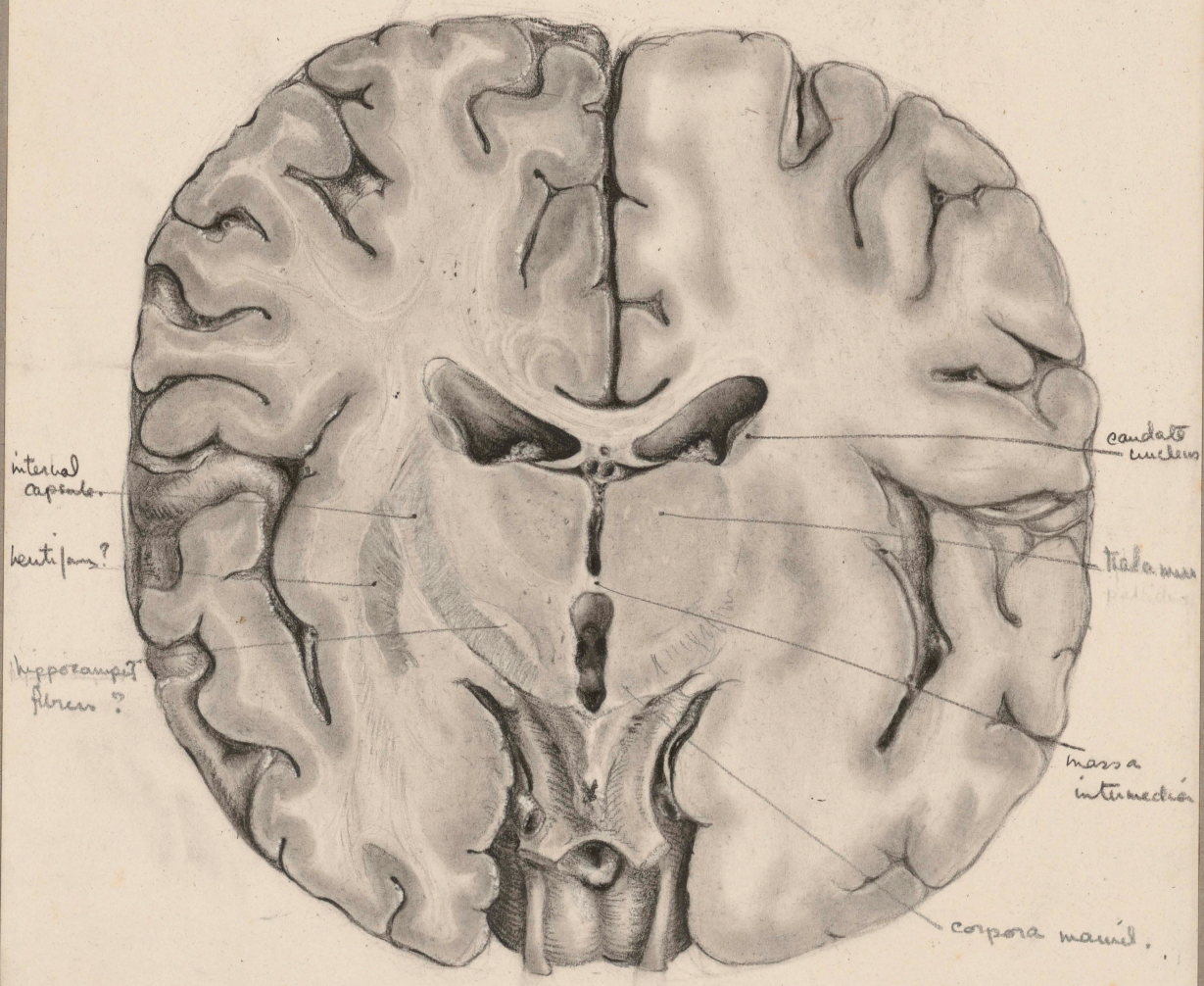


J. W. D. all 55 -









internal
capsule.

ventr. lam?

hippocampus?
fibers?

caudate
nucleus

thalamus
pedunculus

massa
intermedia

corpora mamill.



